Clin. Cardiol. 11, 553-562 (1988)

Accuracy of M-Mode and Two-Dimensional Echocardiography in the Diagnosis of Aortic Dissection: An Experience with 128 Cases

R. P. ROUDAUT, M.D., M. A. BILLES, M.D., P. GOSSE, M.D., C. DEVILLE, M.D., E. BAUDET, M.D., F. FONTAN, M.D., P. BESSE, M.D., H. BRICAUD, M.D., M. DALLOCCHIO, M.D.

Service d'Explorations Paracliniques, Hôpital Cardiologique du Haut Lévêque, Centre Hospitalier et Universitaire de Bordeaux, Bordeaux, France

Summary: The accuracy of combined M-mode and two-dimensional echocardiography in the diagnosis of aortic dissection was evaluated in 673 patients with a clinical suspicion of aortic dissection, over a six-year period. In 128 cases, the diagnosis of aortic dissection was confirmed by angiographic, tomographic (CT scan), or autopsy findings, or during surgery. Two echocardiographic features were found to support a diagnosis of aortic dissection: a dilation of at least one segment of the aorta (sensitivity 95%, specificity 51%) and a typical abnormal linear intraluminal echo corresponding to the intimal flap (sensitivity 67%, specificity 100%). This pathognomonic intimal flap was observed in 86 cases, of which three types could be distinguished: (1) a long oscillating flap (n=15), (2) a long but minimally mobile linear echo which was duplicated and parallel to one or two aortic walls (n=64), (3) a short, double linear image with a rapid systolic motion and high frequency oscillations. These features were found to have a high sensitivity in type I aortic dissection (88%), although in types II and III the sensitivity was much lower. In some cases, a fourth type of abnormal image could be detected: a small intraluminal echo moving in parallel to the aortic wall. This feature should be interpreted with caution since its predictive value for a positive examination was low (48%). Out of 23 cases in which the diagnosis of aortic dissection was suspected on the basis of this doubtful abnormal echo, it was confirmed in only 11 patients. The results in these 128 cases of aortic dissection indicate that two-dimensional echocardiography, which is easily performed at the patient's bedside, could take priority in investigations of this condition. It is extremely sensitive in the diagnosis of ascending aortic dissection, but much less so in the diagnosis of descending aortic dissection.

Key words: M-mode and two-dimensional echocardiography, aortic dissection, aorta

Introduction

Aortic dissection is a cardiovascular emergency with an approximately 40% mortality prior to diagnosis.[1,2] Recent improvements in surgical technique have dramatically changed the outcome of patients with this condition, particularly those with types I or II aortic dissection. Until recently, aortic angiography (aortography) was the only way of establishing diagnosis prior to surgery. This technique is not, however, without risk for the patient.

Nanda *et al.*[3] were the first to emphasize the value of M-mode echocardiography in the diagnosis of aortic dissection. However, many workers have reported false positives using this technique.[4-10] Since the advent of two-dimensional echocardiography, it is possible to study the entire aorta,[11-16] thus enhancing the usefulness of this noninvasive technique in the investigation of aortic dissection.

The purpose of this study was to assess the sensitivity of two-dimensional echocardiography in the diagnosis of aortic dissection. Our investigation was based on a series of 128 cases in whom this diagnosis was confirmed.

Address for reprints:

Raymond P. Roudaut, M.D.
Hôpital Cardiologique du Haut Lévêque
avenue de Magellan
33604 Pessac, France

Received: November 17, 1987
Accepted with revision: May 9, 1988

Methods

Study Cases

From April 1978 to June 1984, 673 patients (503 males, 170 females, mean age of 62 ± 13 years) were referred to our laboratory for investigation of a clinical suspicion of aortic dissection.

Among these patients, the diagnosis of aortic dissection was confirmed in 128 cases on the basis of angiographic (72 patients), tomographic (CT scan) (19 patients), surgical (79 patients), or autopsy (19 patients) findings either alone or in combination. In the other patients, the diagnosis of aortic dissection was excluded by aortography, or scan, or by establishing a benign clinical course during follow-up. At the beginning of the study, an angiographic examination was performed systematically whenever clinical symptoms were suggestive of a diagnosis of aortic dissection. Therefore, as our experience with two-dimensional echocardiography in this condition broadened, we found that when typical echocardiograms were observed, angiographic examination could be avoided. Thus 28 of our patients were operated upon, the diagnosis of aortic dissection being based on echocardiographic criteria only. However, two consecutive false positives observed after 61 cases of aortic dissection led us to perform a further angiography systematically.

The study group of aortic dissection comprised 104 males and 24 females with a mean age of 60 ± 12 (range 24–80). Aortic dissection was acute in 110 cases and subacute or chronic in 18 cases. Clinical symptoms (thoracic pain, aortic regurgitation murmur, disappearance of a pulse) were highly suggestive of an acute aortic dissection in 50 cases. Furthermore, 19 patients had clinical signs of Marfan's syndrome; 91 patients had systemic arterial hypertension, 6 patients had an aortic valve stenosis and in 5 patients an aortic valve replacement was performed some years earlier.

According to De Bakey's classification,[17] 76 cases were type I, 15 type II, and 37 type III aortic dissection. Type I begins in the ascending aorta, progresses distally around the aortic arch and may involve the descending aorta, type II arises in the ascending aorta and extends to the level of the inominate artery, and type III develops distal to the left subclavian artery and may extend into the abdomen.

Echocardiography

In all patients M-mode and two-dimensional echocardiography was the first examination performed. A Varian V 3000 or a Roche Kontron RT400-phased array sector scanner was used and recordings were made as necessary, regardless of the time of day or night, by a small group of physicians.

The two-dimensional echocardiogram was recorded with a systematic approach in order to visualize the entire aorta. During the first three years of this study we investigated the ascending aorta by left parasternal views (long- and short-axis) and apical views (four- and two-chamber views). For the study of the aortic arch the probe was placed in the suprasternal notch, and the descending aorta was studied by parasternal, subcostal, and abdominal views. During the latter three years, we tried to record the aorta systematically by right parasternal and dorsal (left paravertebral) views. The patients were examined in the following positions: left lateral decubitus (left parasternal and apical position of the probe), supine (subcostal and abdominal position), supine with hyperextension of the neck (suprasternal notch), right lateral decubitus (right parasternal, second right interspace and dorsal left paravertebral position).

In all cases, echocardiographic data were stored on video tape. Polaroid films were taken of the most relevant two-dimensional echocardiography still frames.

Two essential diagnostic criteria were looked for on the echocardiographic recordings:

1. Dilation of at least one segment of the aorta. In our experience, the aorta may be considered as dilated if the diameter is more than 40 mm at the level of the ascending aorta, 35 mm at the level of the aortic arch and thoracic descending aorta, 30 mm at the level of the abdominal aorta.
2. An abnormal linear image in the lumen, suggesting an intimal flap.

According to previous studies, a combination of these two criteria can be considered as diagnostic evidence for aortic dissection.

To evaluate the diagnostic value of the aortic enlargement, the internal diameter of the aorta was compared with a mean value from a control group of 40 adult patients with various cardiac diseases but without aortic wall pathology. In addition, since many patients with aortic dissection have associated hypertension (91/128) they were compared to a similarly matched hypertensive population without aortic dissection. We also looked for evidence of pericardial effusion and the presence of aortic regurgitation (mitral fluttering).

Echo-Doppler technique was not performed in this series.

Statistical Analysis

The following definitions were used:

Sensitivity: true positives/true positives + false negatives

Specificity: true negatives/true negatives + false positives

Predictive value of a positive examination: true positives/true positives + false positives.

Predictive value for a negative examination: true negatives/true negatives + false negatives.

TABLE I Sensitivity, specificity, and predictive value of the different criteria of aortic dissection

Criteria	Clinical suspicion AD n=673	Confirmed AD n=128	Sensitivity	Specificity	Predictive value positive exam	Predictive value negative exam
Dilatation aorta	392	122	95	51	31	58
Abnormal linear image in the lumen	109	97	76	98	89	95
Long	86	86	67	100	100	93
Short	23	11	8.6	98	48	85
Pericardial effusion	82	47	37	94	48	88
Aortic regurgitation	73	48	37.5	96	66	88

Calculations were performed for each evaluated echocardiographic criterion. Statistical comparisons between pairs of means were evaluated using Student's *t* test.

Results

The echocardiogram was technically very difficult and of poor quality in 13 cases of aortic dissection (10%) (2 cases with type I and II, 11 cases with type III aortic dissection). In the remaining 115 patients, the echocardiogram was judged to be technically adequate and the criterion previously described could be analyzed for sensitivity and specificity.

Aortic Dilation

A dilation of at least one segment of the aorta was observed in 392 patients out of 673 with a clinical suspicion of aortic dissection. This latter was confirmed in only 122.

The internal maximal diameter of the ascending aorta was measured in all patients with type I and II aortic dissection (n=91). The mean value was 55.7±12.4 mm (range: 35–90). This value was significantly greater than that found in the 40 control subjects without aortic wall pathology 32±8mm (range: 25–38) $p<0.01$. The difference is still significant when comparing hypertensive patients with (50.8±13) and without aortic dissection (36.1±5.4) $p<0.001$.

The diameter of the transverse aorta (measured by suprasternal view) was 39.7±6.7 mm (range: 25–55) in 67 out of 79 patients with type I aortic dissection in whom it could be measured, as compared to 27±6 mm (range: 24–32) in the control group ($p<0.01$).

The diameter of the descending abdominal aorta was measured in 91 cases of type I and III aortic dissection. The mean value was 31.2±7.4 mm (range: 25–50). This value was significantly higher than that measured in the control group (21±6 mm, range: 17–31, $p<0.01$).

Finally, in our experience, the diameter of at least one segment of the aorta is in most of the cases increased (122 of 128 cases), although a normal value does not exclude an aortic dissection. The sensitivity of the dilation criterion is 95%, although the specificity is only 51% (Table I).

Abnormal Linear Intraluminal Image

In this study, two types of abnormal intraluminal echoes were seen, some of which were very suggestive of an intimal flap (n=86), others were doubtful (n=23) (Table II).

For the *very suggestive ones*, three features were found.

The first is a long (> 1 cm), oscillating intimal flap with a sail-like motion. It is also generally thin, bright, sometimes with high frequency oscillations, or attached by one point to the aortic wall. In some cases, a linear echo criss-crossing or dividing the aorta perpendicularly is highly diagnostic of an intimal flap. This feature was observed in 15 cases (Figs. 1 and 2), especially in the ascending and transverse portions of the aorta.

The second, more frequent feature (64 cases), is also long but minimally mobile; it is parallel to one or two aortic walls. On the simultaneous M-mode recording this abnormal echo may be minimally pulsating or fluttering with high frequency oscillations.

The third aspect, observed in 7 cases, is short but double with an abrupt systolic motion and/or high frequency oscillations.

TABLE II Distribution of the abnormal intraluminal echo with regard to the anatomical type of dissection

	128 Aortic dissection—2-D echo		
Anatomical type	I	II	III
N	76	15	37
Doubtful 2-D echo diagnosis	1 (1.3%)	4 (26.6%)	6 (16.2%)
Obvious 2-D echo diagnosis	66 (86.8%)	7 (46.6%)	13 (35%)

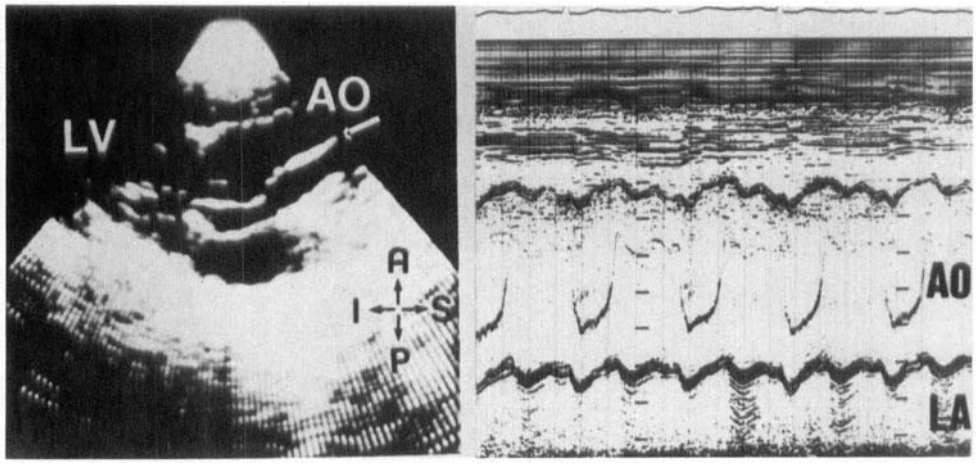

FIG. 1 First typical aspect of aortic dissection with an "oscillating flap." On parasternal long-axis view, we can visualize the two main criteria of aortic dissection: (1) The dilation of the aorta and (2) the abnormal linear image in the lumen; the simultaneous M-mode recording shows the very suggestive "sail-like" motion of the intimal flap. Ao: aorta. LA: left atrium, LV: left ventricle, A: anterior, P: posterior, I: inferior, S: superior.

In all cases, these abnormal echoes were seen constantly in at least two ultrasonic planes. The sensitivity of this typical abnormal intraluminal image was 67% and its specificity 100%.

Furthermore, a thrombus was detected at the level of the descending aorta in 4 patients (2 with acute, and 2 with chronic aortic dissection). In these cases, the intimal flap was immobile.

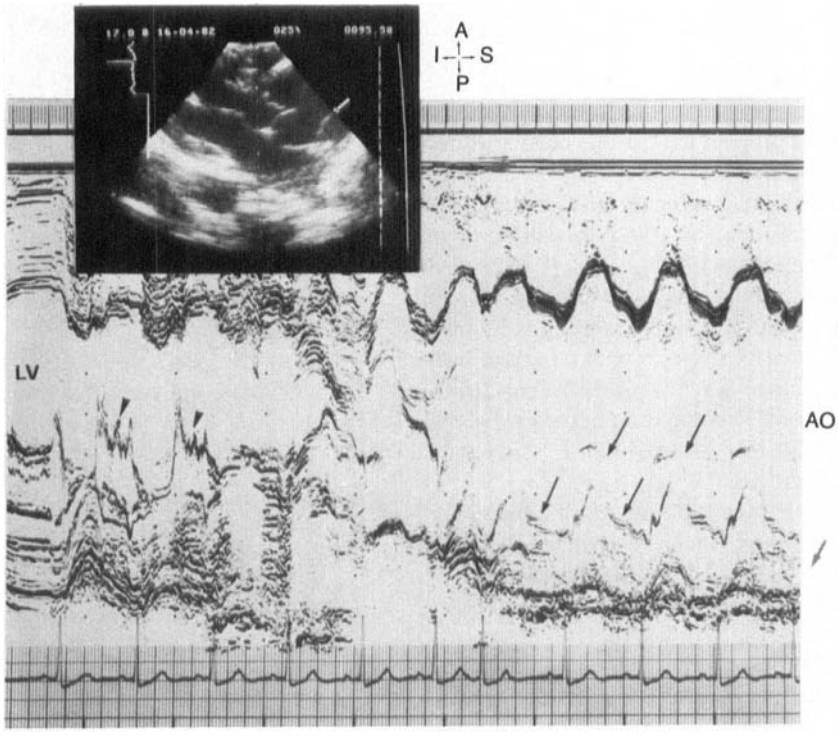

FIG. 2 Second example of the typical feature. The abnormal echo is attached to the aortic wall two centimeters above the aortic cups at the level of a dilated aorta. On the M-mode echo we can see at the level of the aorta the intimal flap (arrow). At the level of the aortic valves, we can notice a premature opening which suggests a severe aortic regurgitation. Ao: aorta, LV: left ventricle, A: anterior, P: posterior, I: inferior, S: superior.

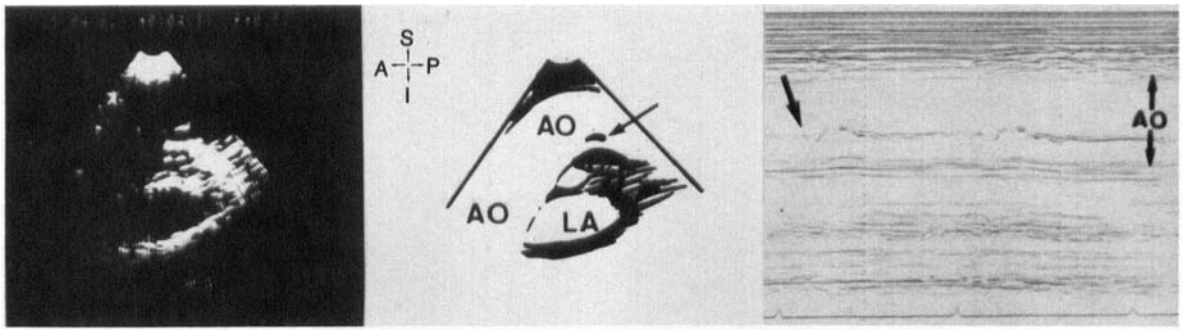

FIG. 3 Example of a tricky case. On right parasternal long-axis view, we observed a very localized and short echo at the level of the aortic arch. The M-mode recorded simultaneously showed a minimally mobile linear echo. The diagnosis of aortic dissection was confirmed in this case by angiography. Ao: aorta, LA: left atrium, A: anterior, S: superior, P: posterior, I: inferior.

In the group of patients with type I aortic dissection, one of these three typical features was recorded 60 times at the level of the ascending aorta, 35 times at the level of thoracic ascending aorta, and 20 times at the level of the abdominal aorta. In the group of patients with a type II aortic dissection, this intimal flap was seen in 10 cases at the level of the ascending aorta. In the type III aortic dissection, the image was recorded in 10 cases at the level of the thoracic descending aorta and in 10 cases at the level of the descending aorta. The right parasternal view displayed these abnormal images in 13 cases and the dorsal view in 9 cases.

More *doubtful abnormal echoes* were observed in 23 patients. The diagnosis of aortic dissection was confirmed either by angiography or CT scan in only 11 of these patients (12 false positives).

Abnormal intraluminal echo can be considered doubtful when localized, short (often less than 1 cm), inconstant, parallel to the aortic wall, immobile or minimally mobile, or when seen on one view only. Such images were observed in 23 patients and did not correspond to an aortic dissection in 12 cases (false positives) (Figs. 3 and 4). In 7 of these 12 patients this false positive image was seen at the level of the ascending aorta and 5 of those patients had an aortic root aneurysm. A false positive echo was localized at the level of the aortic arch in 1 case, and at the level of the abdominal aorta in 4 cases.

One patient was falsely diagnosed as having a type I aortic dissection on the basis of echocardiographic findings, but had a true type III (Fig. 5). In this patient, the ascending aorta was enlarged (48 mm), and on a parasternal long-axis view a small echo detaching from the posteri-

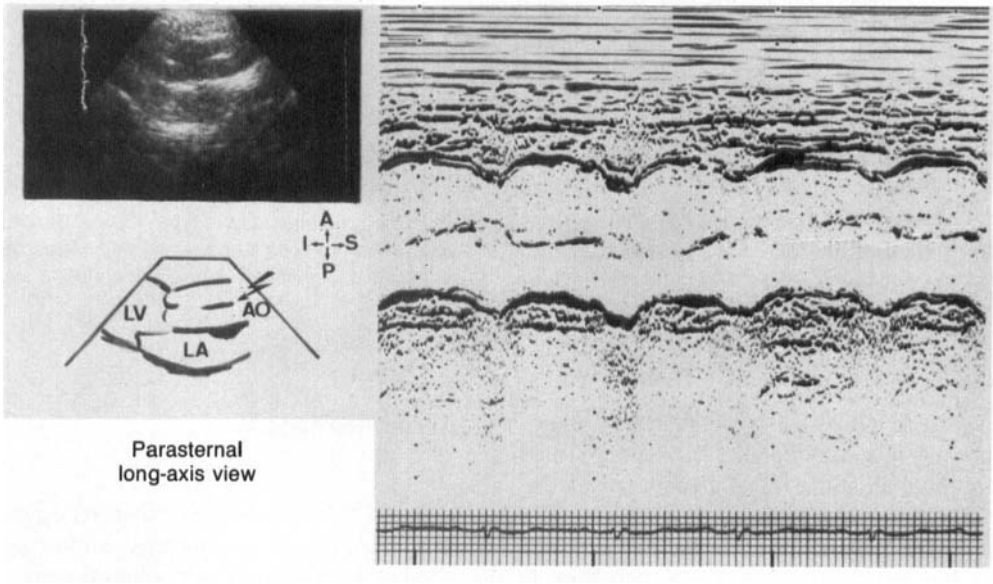

FIG. 4 Example of a false positive diagnosis of intimal flap: an abnormal linear and slightly mobile echo was recorded at the level of a dilated and calcified ascending aorta. Ao: aorta, LA: left atrium, LV: left ventricle, A: anterior, P: posterior, I: inferior, S: superior.

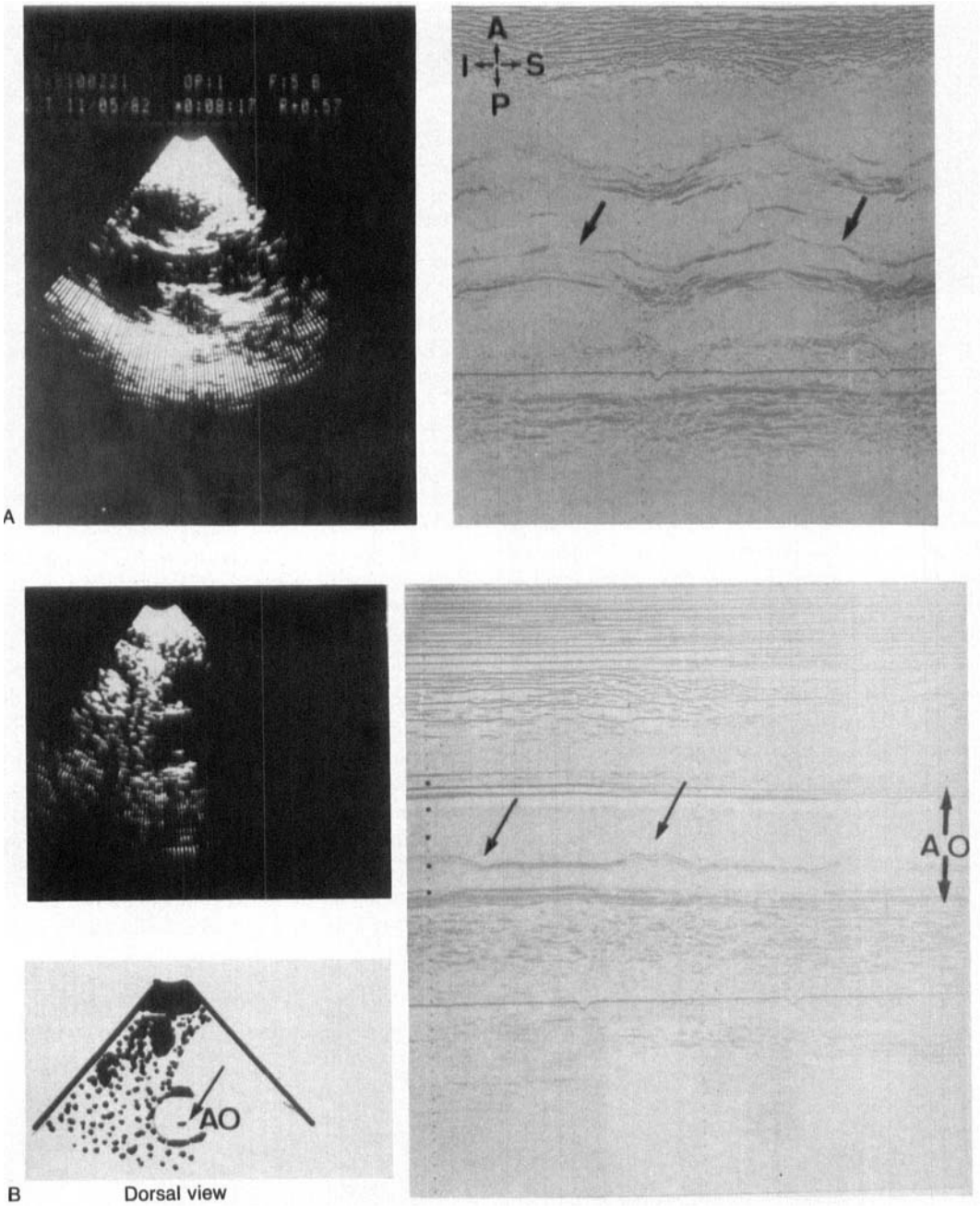

FIG. 5 Example of a false positive echocardiographic diagnosis of type I aortic dissection in a case of type III aortic dissection. (A) Parasternal long-axis view at the level of a dilated ascending aorta, we can see a small abnormal echo which seems to duplicate the posterior aortic wall. (B) Dorsal view, a pulsating intimal flap is recorded at the level of the descending thoracic aorta. Ao: aorta, A: anterior, I: inferior, P: posterior, S: superior.

or aortic ring was seen. On M-mode simultaneous recordings, this abnormal echo was parallel to and duplicated the posterior aortic wall (Fig. 5a). An abnormal pulsating intraluminal echo was also recorded from a dorsal view at the level of the descending thoracic aorta (Fig. 5b). The diagnosis of type III aortic dissection was confirmed at surgery but the heavily calcified aortic root was found to be free of dissection.

Aortic Regurgitation

Based on clinical signs and on echocardiographic findings (mitral, septal fluttering) aortic regurgitation was present in 73 patients in this series. Aortic dissection was found in 48 of these patients (37.5% sensitivity and 96% specificity). Aortic cusp prolapse was observed in 4 cases.

In one case, a severe aortic regurgitation was associated with a premature closing of the mitral valve and with a premature opening of the aortic valve. Early closure of the aortic valve was recorded in five patients with type I or II aortic dissection.

Pericardial Effusion

Among the 82 patients who had signs of pericardial effusion, 47 patients had an aortic dissection (sensitivity: 37%, specificity: 94%). Only 2 patients presented with signs of tamponade.

Length of the Aortic Dissection

The proximal level of the aortic dissection could be studied in 63 cases of type I and II, and in 6 cases of type III aortic dissection. The intimal tear could be recorded in only 3 patients. The length of the intimal flap was variable, depending on the type of the aortic dissection. In 15 cases with type I aortic dissection, we recorded an intimal flap inside the three segments of the aorta (the ascending aorta, the aortic arch, and the descending aorta) (Fig. 6). This abnormal echo could be seen in only two segments (the ascending aorta and aortic arch or descending aorta in 25 cases) and in only the ascending aorta in 25 patients, in only the aortic arch in two. It was not possible to distinguish between type I and type II aortic dissection in the latter patients using echocardiography alone.

An intimal flap was also found in the brachiocephalic arteries in 9 cases with type I aortic dissection.

In type III aortic dissection, we were able to record an intimal flap in two segments (the thoracic descending aorta and the abdominal aorta) in 5 patients; in only one segment in 10 patients (at the level of the descending thoracic aorta in 5 cases and on the abdominal aorta in another 5 cases).

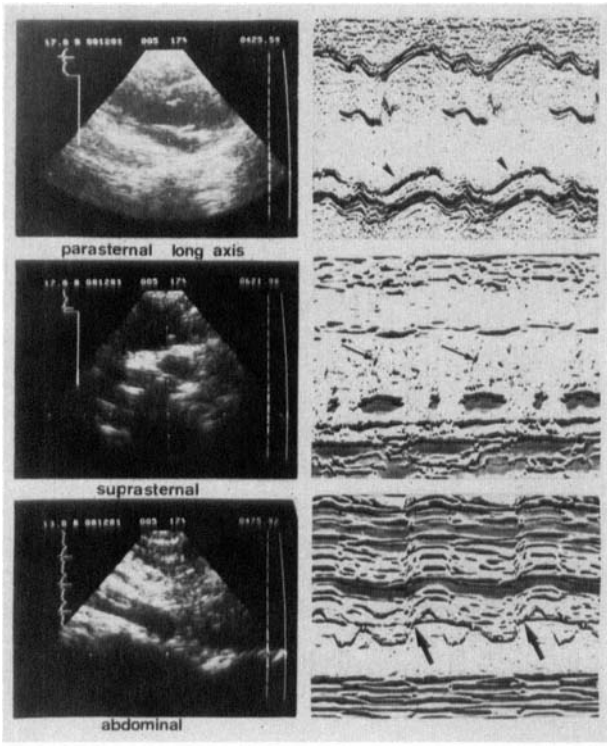

FIG. 6 Example of a type I aortic dissection. (Top) the dilation of the aorta is maximal at the level of the ascending aorta (48 mm). However the intimal flap is quite immobile at this level, but pulsating at the level of the aortic arch (middle) and waving at the level of the abdominal aorta (bottom).

Chronic Aortic Dissection

Subacute or chronic aortic dissection was found in 18 patients; 7 were type I, 11 were type III. The diagnosis of aortic dissection was not possible by two-dimensional echo in 3 patients and was doubtful in 2 patients. Three patients with type I aortic dissection had typical hypermobile intimal flap. In the other cases, the intimal flap was typically long and minimally mobile. A thrombus was detected in 2 patients.

Discussion

In 1972, Millward *et al.*[7] first reported on the use of M-mode echocardiography in the diagnosis of aortic root dissection. In 1973, Nanda *et al.*[3] reported M-mode echocardiographic findings in six patients with an aortic root dissection that was confirmed by angiography, surgery, and autopsy.

However M-mode echocardiography can often lead to a false positive diagnosis.

Recent reports have suggested that two-dimensional echocardiography might be of more value than M-mode echocardiography in the diagnosis of aortic aneurysm and aortic dissection, particularly since two criteria need to be fulfilled for diagnosis of aortic dissection, namely: a dilatation of one segment of the aorta, and an abnormal linear intraluminal echo corresponding to the intimal flap.[18-27] However, these reports were based on a limited number of patients, and the sensitivity and specificity of these criteria have not been accurately assessed. In our experience with M-mode and two-dimensional echocardiography, based on a very large group of patients from the entire Southwest of France, the sensitivity and the specificity of the typical abnormal intraluminal echoes were 67% and 100%, respectively.

A diagnosis of aortic dissection can only be considered certain if these abnormal linear intraluminal echoes are present. Three main features may be observed:

First, an oscilling flap which is linear, long (> 1 cm), thin, bright, mobile in the lumen and undulating, vibrating or waving with a sail like motion. This image should

be observed on at least two ultrasonic views (in the same or in two different aortic segments).

Second, a long duplication with parallel wall motion of one or two aortic walls. In these cases, the diagnosis is easy if the abnormal echo is attached to one part of the aortic wall, and if there is systolic pulsation or fluttering.

Third, the abnormal intraluminal echo is short but is highly suggestive of aortic dissection if it appears double or multiple and presents an abrupt, rapid systolic motion or high frequency vibrations; reduplication of aortic valve echoes or prolapse of the intimal flap into the left ventricular outflow tract have also been reported.[28-30] Other echocardiographic features have been described, including detection of thrombus at the level of the aortic dissection and intracavitary echoes especially in type III aortic dissection.[31]

Four factors may account for false negative images: (1) A poor ultrasonic window: this problem is often encountered in overweight patients. (2) A localized aortic dissection (type II or III).[26] (3) An acute aortic dissection studied in the first few hours after onset: in one of our cases, the first examination one hour after the patient started complaining of thoracic pain was negative, while 24 h later an intimal flap was detected. (4) An artificial dropout of echoes, when the intimal flap is spiral shaped[21] so that the aortic tear lies in a plane tangential or parallel to the beam.

False negative images were seen in 24% of our patients with M-mode and two-dimensional echocardiography and in 15% with angiography. CT scan appears to be more accurate than echocardiography or angiography since it correctly diagnosed aortic dissection in all 19 cases where it was carried out. However, two-dimensional echocardiography can be more easily and rapidly performed in an intensive care unit at any time of day or night.

False positive images have been reported by some authors. Some of these are likely to be due to setting the gain too high. These spurious echoes are not reproducible and are not found in multiple views and probe positions. They disappear with adjustment of gain or reject. Other artifacts are due to reverberations from a calcified aortic ring or aortic wall, or to extraneous echoes emanating from the sides of the lumen. In general, these echoes are short, and follow the complete cycle of the aortic structure. M-mode recordings of this abnormal image are crucial in establishing the diagnosis. Pulsation or fluttering is strongly suggestive of dissection. This represents a potential error which can be avoided by combining M-mode and two-dimensional echocardiography, and it underlines the complementary nature of these two techniques. Some authors have also reported false positive echocardiographic images of an intimal flap in cases of aortic root aneurysm[21] or abscess,[32] or mobile atherosclerotic plaque.[33] Other potential pitfalls may be related to the presence of extra-aortic hematoma, tumor, fat, or superimposed vessels particularly at the level of the aortic arch and the descending aorta. Prominent venous valves within large inominate veins may be mistaken for an intimal flap in the aortic arch.[34] Over the six-year period of the study we have constantly improved the technique, and the results obtained now are superior to those in the initial stages of this research.

The mechanism of the intimal flap motion has not been clearly elucidated. According to Smuckler *et al.*,[24] the presence of a parallel wall motion and the absence of an oscillating flap may help to differentiate a chronic from an acute aortic dissection. Ferrier *et al.*[35] reported that an oscillating "intimo-intimal flap" was always present in acute aortic dissection without thrombosis of the false aortic lumen. However, Okamoto *et al.*,[36] using a Doppler technique, showed that the existence of a mobile flap indicated the presence of blood flow in both the true and the false lumens. An akinetic flap, however, does not invariably exclude the absence of blood in either the true or the false lumen. In our experience, the intimal flap may be motionless at one level of the aorta and undulating elsewhere (Fig. 6).

Type I and II Versus Type III Aortic Dissection

Our experience suggests that two-dimensional echocardiography is a useful and accurate method for detection of types I and II aortic dissection. The diagnosis of type III aortic dissection is more difficult to establish mainly because the descending thoracic aorta cannot be recorded easily. Recently, some authors have pointed out the value of transesophageal echocardiography in the condition.[37]

Echo-Doppler technique was not performed in this series. However, we actually think that this technique may be useful in the positive diagnosis of aortic dissection, particularly in doubtful cases: a peculiar click sound is systematically heard when the sample volume is placed at the level of the mobile intimal flap, furthermore different blood flow velocities may be identified in the false and the true lumen.

Pulsed Doppler studies are also useful in diagnosing reopening of aortic dissection in a patient with previous surgery.[3,36,38]

CT Scan

In this study, CT scan was always positive when it was performed. But according to Iliceto *et al.*,[39] two dimensional echo appears to be superior in the recognition of an intimal flap, whereas CT scan allows a better recognition of the extension and tissue modification of the aneurysm.[40]

Practical Implications

In our institution, two-dimensional echo is currently considered as the main and the first noninvasive diagnostic technique when aortic dissection is suspected. However,

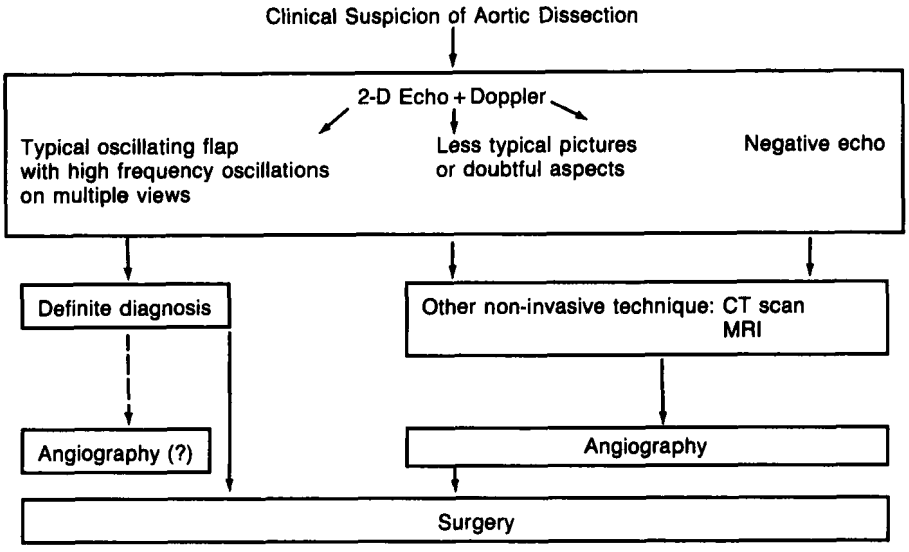

FIG. 7 Decision tree in a patient with clinical suspicion of aortic dissection (MRI: magnetic resonance imaging).

this examination requires a good technician and a complete systematic approach of the entire aorta by multiple views (parasternal, left and right, long- and short-axis views, suprasternal, apical, dorsal, subcostal) (Fig. 7).

This technique offers advantages over and above its accuracy. It is safe and can be performed quickly at the bedside at any time of day or night. In patients presenting with isolated chest pain without electrical or biochemical signs of myocardial infarction, a negative echocardiogram is reassuring when excluding a diagnosis of aortic dissection, particularly in type I cases. It can obviate the need for other investigations. However, when the symptoms are highly suggestive of aortic-dissection, a negative or doubtful two-dimensional echo cannot exclude dissection. In such cases, CT scan and or angiography are required. In our experience, 28 of our aortic dissection patients have been operated upon without angiography on the basis of clinical and echocardiographic data only. Unfortunately, two other consecutive patients have been operated on and were false positive. One of them was falsely diagnosed as having a type I aortic dissection on the basis of echocardiographic findings but had a true type III aortic dissection. Therefore, we actually think that angiography must be performed except when very typical intimal flap is observed: hypermobile flap with high frequency velocities, and on multiple views. In these cases, and from a practical point of view, the main questions are to determine whether the dissection is localized in the ascending aorta and whether renal function is satisfactory. These two factors alone justify emergency intervention on the ascending aorta due to the high risk of rupture of this segment. Ideally, one should be able to localize the intimal tear and the extension of the dissecting hematoma precisely. In fact, the intimal tear is localized at the level of the ascending aorta in 60 to 65% of cases. According to Cipriano *et al.*,[41] in the rare case of retrograde aortic dissection with an intimal tear situated in the aortic arch, replacement of the ascending aorta alone is frequently life saving, even though continuity of the aortic intima is not restored by resection of the intimal tear. The aortic arch and descending aorta can be replaced later with a graft.

Conclusion

In conclusion, this study demonstrated that combined M-mode and two-dimensional echocardiography is a reliable technique in the evaluation of patients with suspected aortic dissection. Two criteria are highly suggestive of this diagnosis when found at the same anatomical level: a dilatation of at least one segment of the aorta, and more importantly, an abnormal typical linear intraluminal echo corresponding to the intimal flap. The sensitivity and specificity of the latter criteria were 67% and 100%, respectively. Two-dimensional echo is extremely sensitive in the diagnosis of ascending aortic aneurysm and much less sensitive in the diagnosis of descending thoracic aorta aneurysm. Therefore, if a descending thoracic aortic aneurysm is suspected, two-dimensional echo combined with another noninvasive technique such as CT scanning or magnetic resonance imaging may increase the sensitivity.

Our experience with 128 cases of aortic dissection studied by two-dimensional echocardiography suggests that this easily performed technique could take priority in the investigation of this condition.

References

1. Wheat MW: Acute dissecting aneurysms of the aorta: Diagnosis and treatment-1979. *Am Heart J* 99, 373 (1980)

2. Craig Miller D, Stinson EB, Oyer PE, Rossiter SJ, Reitz BA, Griepp RB, Shunway NE: Operative treatment of aortic dissections. Experience with 125 patients over a sixteen years period. *J Thorac Cardiovasc Surg* 78, 365 (1979)
3. Nanda NC, Gramiak R, Shah PM: Diagnosis of aortic root dissection by echocardiography. *Circulation* 48, 506 (1973)
4. Hirschfeld DS, Rodriguez HJ, Schiller NB: Duplication of aortic wall seen by echocardiography. *Br Heart J* 38, 943 (1976)
5. Kolettis M, Toutouzas P, Avgoustakis D: False echocardiographic diagnosis of aortic root dissection in case of abdominal aortic dissection. *Br Heart J* 45, 602 (1981)
6. Kruger SK, Starke H, Forker AD, Eliot RS: Echocardiographic mimics of aortic root dissection. *Chest* 67, 41 (1975)
7. Millward DK, Robinson NJ, Craige E: Dissecting aortic aneurysm diagnosed by echocardiography in a patient with rupture of the aneurysm into the right atrium. Rare cause of continuous murmur. *Am J Cardiol* 30, 427 (1972)
8. Moothart RW, Spangler RD, Blount SG: Echocardiography in aortic root dissection and dilation. *Am J Cardiol* 36, 11 (1975)
9. Orzan F, Ottino G, Dissumma M, Carini G: Pericardial effusion simulating aortic dissection. *Br Heart J* 45, 207 (1981)
10. Yoshikawa J, Owaki T, Kato H: Ultrasonic features of anomalous origin of the left coronary artery from pulmonary artery. *Jap Heart J* 19, 45 (1978)
11. Bansal RC, Tajik AJ, Seward JB, Offord KP: Feasibility of detailed two dimensional echocardiographic examination in adults. *Mayo Clin Proc* 55, 291 (1980)
12. Come PC: Improved cross sectional echocardiographic technique for visualization of the retrocardiac descending aorta in its long axis. *Am J Cardiol* 51, 1029 (1983)
13. D'Cruz IA, Jain DP, Hirsch L, Levinsky R, Cohen HC, Glick G: Echocardiographic diagnosis of dilation of the ascending aorta using right parasternal scanning. *Radiology* 129, 465 (1978)
14. De Maria AN, Bommer W, Neumann AB, Weinert L, Bogren H, Mason DT: Identification and localization of aneurysms of the ascending aorta by cross sectional echocardiography. *Circulation* 4, 59 (1979)
15. Kasper W, Meinertz T, Kersting F, Lang K, Just H: Diagnosis of dissecting aorta aneurysm with suprasternal echocardiography. *Am J Cardiol* 42, 291 (1978)
16. Mintz GS, Kotler MN, Segal BL, Parry NR: Two-dimensional recognition of the echocardiographic descending thoracic aorta. *Am J Cardiol* 44, 232 (1979)
17. De Bakey ME, Henry WS, Cooley DA, Morris GC, Craxford ES, Beall AC: Surgical management of dissection aneurysms of the aorta. *J Thorac Cardiovasc Surg* 49, 130 (1965)
18. Bubenheimer P, Schmuziger M, Roskamm H: Ein-und zweidimensionale Echographie bei Aneurysmen und Dissektionen der Aorta. *Herz* 5, 226 (1980)
19. D'Cruz IA, Jain M, Campbell C, Goldbarg AN: Ultrasound visualization of aortic dissection by right parasternal scanning, including systolic flutter of the intimal flap. *Chest* 80, 239 (1981)
20. Gateau P, Billes MA, Page A, Roudaut R, Dallocchio M, Besse P: Contribution de l'échocardiographie bidimensionnelle au diagnostic des dissections aortiques en urgence. *Arch Mal Coeur* 75, 179 (1982)
21. Iliceto S, Antonelli G, Biasco G, Rizzon P: Two dimensional echocardiographic evaluation of aneurysm of the descending thoracic aorta. *Circulation* 55, 1045 (1982)
22. Matsumoto M, Matsuo H, Ohara T, Yoshioka Y, Abe H: A two dimensional echocardiographic approach to dissecting aneurysms of the aorta to prevent false positive diagnoses. *Radiology* 127, 491 (1978)
23. Roudaut R, Billes MA, Gateau P, Besse P, Dallocchio M: Two-dimensional echocardiography in the diagnosis of aortic dissection in 41 patients. *Circulation* 64 IV, 314 (1981)
24. Smuckler AL, Nomeir AM, Watts LE, Hackshaw BT: Echocardiographic diagnosis of aortic root dissection by M mode and two-dimensional techniques. *Am Heart J* 103, 897 (1982)
25. Victor MF, Mintz GS, Kotler MN, Wilson AR, Segal BL: Two-dimensional echocardiographic diagnosis of aortic dissection. *Am J Cardiol* 48, 1155 (1981)
26. McLeod AA, Monoghan MJ, Richardson PJ, Jackson G, Jewitt DE: Diagnosis of acute aortic dissection by M mode and cross sectional echocardiography: A five years experience. *Eur Heart J* 4, 196 (1983)
27. Granato JE, Dee P, Gibson RS: Utility of two-dimensional echocardiography in suspected ascending aorta dissection. *Am J Cardiol* 56, 124 (1985)
28. Stever SW, Parameswaran R, Goldshlack P, Goldberg H: Unusual echocardiographic findings in aortic dissection. *Arch Intern Med* 142 (1982)
29. Cohen ISH, Wharton T: Duplication of aortic cusp. New M mode echocardiographic sign of intimal tear in aortic dissection. *Br Heart J* 67, 173 (1982)
30. Sraow JS, Desser KB, Benchimol A, De Saineto A, Peebles S: Two-dimensional echocardiographic recognition of an aortic intimal flap prolapsing into the left ventricular outflow tract. *J Am Coll Cardiol* 4, 180 (1984)
31. Panidis IP, Kotler MN, Mintz GS, Ross J: Intracavitary echoes in the aortic arch in type III aortic dissection. *Am J Cardiol* 54, 1159 (1984)
32. Scanlan JG, Seward JB, Tajik AJ: Valve ring abscess in infective endocarditis: Visualization with wide angle two-dimensional echocardiography. *Am J Cardiol* 49, 1794 (1982)
33. Nestico P, Panidis I, Kotler M, Mintz G, Mattleman S, Ross J: Atherosclerotic plaque simulating aortic dissection by echocardiography and angiography. *Am Heart J* 109, 607 (1985)
34. Miller JL, Nanda NC, Singh RP, Mathew T, Iliceto S, Rizzon P: Echocardiographic diagnosis of aortic aneurysm and dissection. *Echocardiography* 1, 507 (1984)
35. Ferrier A, Guertet P, Farcot JC, Dubourg O, Terdjman M, Bardet J, Bourdarias JP: Significance of mobile intimal flap in aortic dissection elucidated by echocardiography. (abstr) *Circulation* (suppl III), 68 282 (1983)
36. Okamoto M, Kinoshita N, Miyatake K, Beppu S, Samakibara H, Nimllra Y: Detection and analysis of blood flow in aortic dissection with two dimensional echo doppler technique. *In Excerpta Medica International Congress*, Series No. 547, Excerpta Medica Amsterdam (1981) 144
37. Borner N, Erbel R, Braun B, Henkel B, Meyrer J, Rumpelt J: Diagnosis of aortic dissection by transoesophageal echocardiography. *Am J Cardiol* 54, 1157 (1984)
38. Mathew T, Nanda NC: Two-dimensional and doppler echocardiographic evaluation of aortic aneurysm and dissection. *Am J Cardiol* 54, 379 (1984)
39. Iliceto S, Ettore G, Francioso G, Antonelli G, Biasco G, Rizzon P: Diagnosis of aneurysm of the thoracic aorta. Comparison between two noninvasive techniques: Two-dimensional echocardiography and computed tomography. *Eur Heart J* 5, 545 (1984)
40. Goldman AP, Kotler MN, Scanlan MH, Ostrum B, Parameswaran R, Parry WR: The complementary role of magnetic resonance imaging, Doppler echocardiography and computed tomography in the diagnosis of dissecting thoracic aneurysms. *Am Heart J* 111, 980 (1986)
41. Cipriano PR, Griepp RB: Acute retrograd dissection of the ascending thoracic aorta. *Am J Cardiol* 43, 520 (1979)